

The National Board Dental Hygiene Examination (NBDHE)

Sample Questions

Which muscle is innervated by the hypoglossal nerve?

- A. Genioglossus (Key)
- B. Inferior pharyngeal constrictor
- C. Palatoglossus
- D. Palatopharyngeus

Content Area: Scientific Basis
for Dental Hygiene Practice

Which virus causes hairy leukoplakia?

- A. Epstein-Barr (Key)
- B. Herpes simplex
- C. Human immunodeficiency
- D. Human papilloma

Content Area: Scientific Basis
for Dental Hygiene Practice

Which condition may cause Bence-Jones proteins to be found in the urine of a patient?

- A. Leukemia
- B. Multiple myeloma (Key)
- C. Systemic lupus erythematosus
- D. Thalassemia

Content Area: Scientific Basis
for Dental Hygiene Practice

Sample Question 4

Which structure is the natural pacemaker of the heart?

- A. AV node
- B. Bundle of His
- C. Purkinje fiber
- D. SA node (Key)

Content Area: Scientific Basis
for Dental Hygiene Practice

Which dental tissue has a nerve supply?

- A. Cementum
- B. Dentin (Key)
- C. Enamel

Content Area: Scientific Basis
for Dental Hygiene Practice

Natural passive immunity occurs when

- A. antibodies pass from mother to fetus. (Key)
- B. microbes cause disease.
- C. one receives a vaccination.
- D. the immune system produces antibodies.

Content Area: Scientific Basis
for Dental Hygiene Practice

Sample Question 7

The normal value of white blood cells in an individual is

- A. 5,000 - 10,000 per mm^3 . (Key)
- B. 150,000 - 400,000 per mm^3 .
- C. 2.0 million – 3.0 million per mm^3 .
- D. 4.0 million – 7.0 million per mm^3 .

Content Area: Provisions of
Clinical Dental Hygiene
Services

How would a ghost image appear on a panoramic radiograph?

- A. Contralaterally, larger, and higher than the real image (Key)
- B. Contralaterally, smaller, and lower than the real image
- C. On the same side, larger, and higher than the real image
- D. On the same side, smaller, and lower than the real image

Content Area: Provisions of
Clinical Dental Hygiene
Services

Sample Question 9

Which is the ideal trimester to provide dental treatment for a pregnant woman?

- A. First
- B. Second (Key)
- C. Third
- D. No treatment is best

Content Area: Provisions of
Clinical Dental Hygiene
Services

Sample Question 10

The patient complains of a raised, hard, painful structure adjacent to a healing extraction site. This is most likely a/an

- A. alveolar osteitis.
- B. odontogenic cyst.
- C. periodontal abscess.
- D. sequestrum. (Key)

Content Area: Provisions of
Clinical Dental Hygiene
Services

Clinical evidence supporting the need for non-surgical periodontal therapy includes

- A. bleeding on probing. (Key)
- B. dental history.
- C. diagnostic study casts.
- D. gingival recession.

Content Area: Provisions of
Clinical Dental Hygiene
Services

Sample Question 12

Each of the following is a role of the dental hygienist in preventing prescription opioid abuse EXCEPT one. Which is the EXCEPTION?

- A. Assessing patient's medical and dental history
- B. Investigating etiology of patient's pain
- C. Providing patient's preferred pain medication (Key)
- D. Recognizing drug shopping behavior

Content Area: Provisions of
Clinical Dental Hygiene
Services

Which is the rationale for prescribing a medication with a non-child-proof cap for an elderly patient?

- A. Access to care
- B. Attitudinal reactions
- C. Socioeconomic status
- D. Physical limitation (Key)

Content Area: Provisions of
Clinical Dental Hygiene
Services

Sample Question 14

Which question is most likely to elicit accurate information during a health history review?

- A. "How often do you use alcohol?"
- B. "What do you do for your headaches?"
- C. "Have you had this pain for a long time?"
- D. "What medication do you take for your diabetes?" (Key)

Content Area: Provisions of
Clinical Dental Hygiene
Services

Which option exemplifies the behavioral strategy of modeling in pediatric patients?

- A. Demonstrating procedures to the patient
- B. Having patient rehearse appropriate behavior
- C. Observing a sibling during treatment (Key)
- D. Reading a book about visiting the dental office

Content Area: Provisions of
Clinical Dental Hygiene
Services

Which is the most common psychological disorder among adults aged 65 years or above?

- A. Anxiety
- B. Dementia
- C. Depression (Key)
- D. Schizophrenia

Content Area: Provisions of
Clinical Dental Hygiene
Services

Sample Question 17

Which is the primary difference between teeth and implants?

- A. Attachment of bone to teeth is different than to implants
(Key)
- B. Histological changes with inflammation are different
- C. Junctional epithelium cells attach to teeth differently than to implants
- D. Microbiota composition is different

Content Area: Provisions of
Clinical Dental Hygiene
Services

Community Health Scenario followed with 3 questions:

A dental hygienist has recently been contracted to work in a local long-term care facility. The intent is to plan, implement, and evaluate the existing oral health educational and preventive program for the staff and residents at the facility. The hygienist is basing the program on the Healthy People 2020 oral health objectives. The plan includes providing oral health education to the nursing assistants and the use of an optical chair at the facility to provide screenings, prophylaxis, and fluoride treatments.

Which would be the best method of providing daily biofilm removal for the residents?

- A. Manual toothbrush and interdental brush
- B. Manual toothbrush and tufted floss
- C. Powered toothbrush and oral irrigator
- D. Powered toothbrush and floss holder (Key)

Content Area: Community
Health/Research Principles

Which index would be the most appropriate screening tool to assess periodontal health of a patient at this long-term care facility?

- A. GI
- B. DMFS
- C. OHI-S
- D. PSR (Key)

Content Area: Community
Health/Research Principles

Which patient care procedure is evidence-based?

- A. Applying fluoride varnish to teeth (Key)
- B. Demonstrating oil-pulling
- C. Educating the professional staff
- D. Referring patients for treatment

Content Area: Community
Health/Research Principles

Patient Box-Case Sample Exhibits followed by 15 Questions

Patient
Female, 43 years old
Chief Complaint
"My teeth are ugly, and I don't like how my gums are receding on my bottom front teeth."
Background and/or Patient History
High blood pressure and cholesterol Alcohol use disorder-had 8 oz of Vodka in the last 24 hours Gallbladder removed six years ago Gastric bypass surgery 16 years ago
Medications:
atenolol (Tenormin®) medroxyprogesterone (Depo-Provera®) simvastatin (Zocor®)
Last dental visit five years ago for cleaning Smokes 5 to 6 cigars per day/14 years
Current Findings
BP: 128/78 Plaque Index 17% Class I furcation on buccal-3, 14, 15, 30, and 31 Class I mobility on teeth 23 through 26 Gingival recession on facial: 2 mm on teeth 3, 5, 21, 28, and 29. 3 mm on teeth 6 and 27

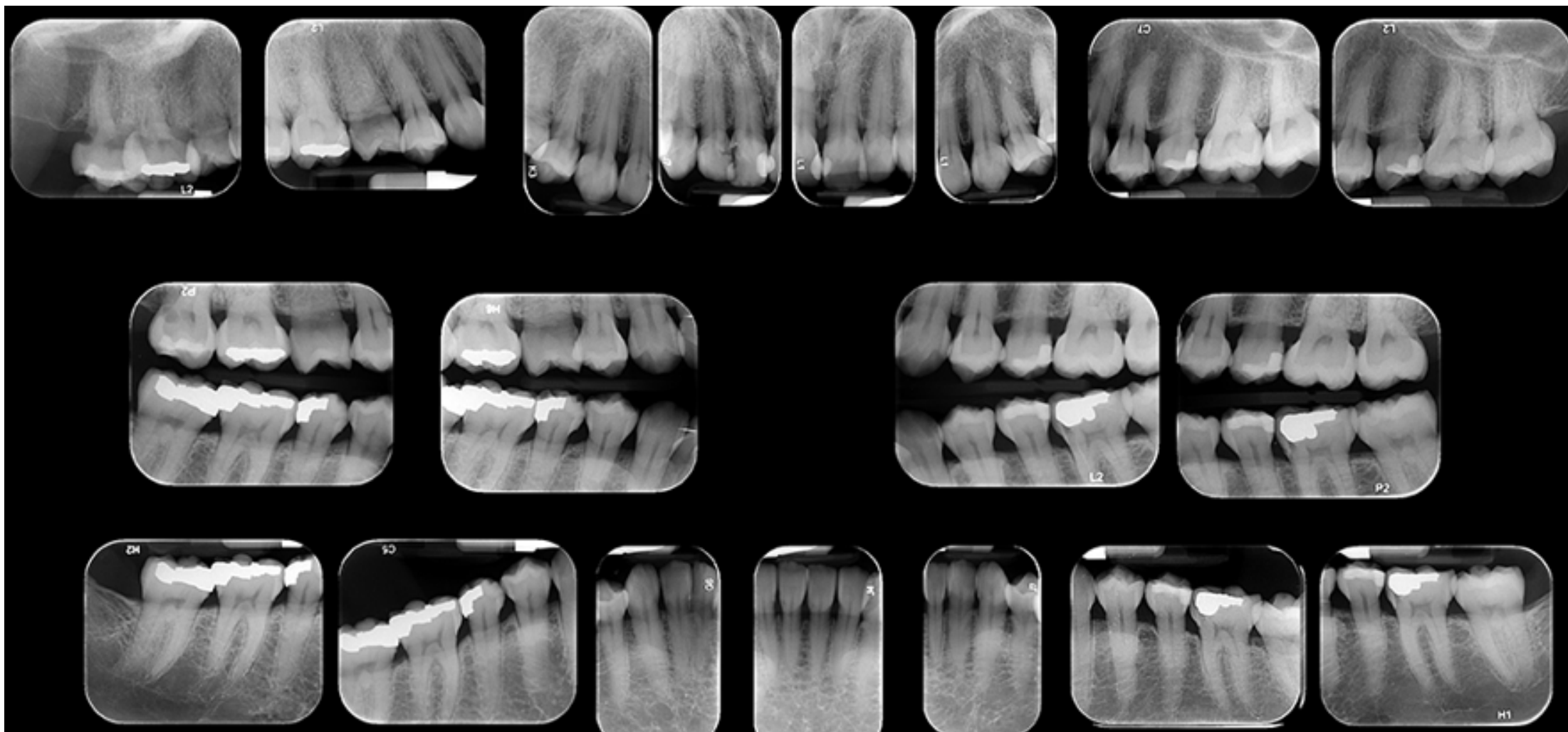
Periodontal Chart

	①	②	③	④	⑤	⑥	⑦	⑧	⑨	⑩	⑪	⑫	⑬	⑭	⑮	⑯
F																
PD		4 3 4	3 2 4	2 2 3	3 2 3	2 2 4	2 2 2	2 2 3	2 2 2	2 2 2	2 2 3	2 2 3	3 2 4	3 2 5	5 2 3	
GM																
CAL																
MGJ																
FG	-	-	-	-	-	-	-	-	-	-	-	-	-	-	-	-
Bld			1											1	1	
Sup																
Sup Bld																
FG	-	-	-	-	-	-	-	-	-	-	-	-	-	-	-	-
MGJ																
CAL																
GM																
PD		4 3 3	4 2 3	3 2 3	3 2 3	3 2 3	3 2 2	2 2 3	3 2 2	2 1 2	3 2 2	3 2 3	3 2 3	4 3 6	4 2 3	
L	M															M
PMB																
PMB																
L	M															M
PD																
GM																
CAL																
MGJ																
FG	-	-	-	-	-	-	-	-	-	-	-	-	-	-	-	-
Bld																
Sup																
Sup Bld																
FG	-	-	1	-	1	-	-	-	-	-	-	-	-	-	-	-
MGJ																
CAL																
GM																
PD		3 3 3	4 2 5	3 1 2	3 2 2	2 2 2	2 1 2	3 1 2	2 1 2	2 2 2	3 1 3	3 2 2	2 2 3	3 2 3	3 2 3	
F																
	⑳	㉑	㉒	㉓	㉔	㉕	㉖	㉗	㉘	㉙	㉚	㉛	㉜	㉝	㉞	㉟

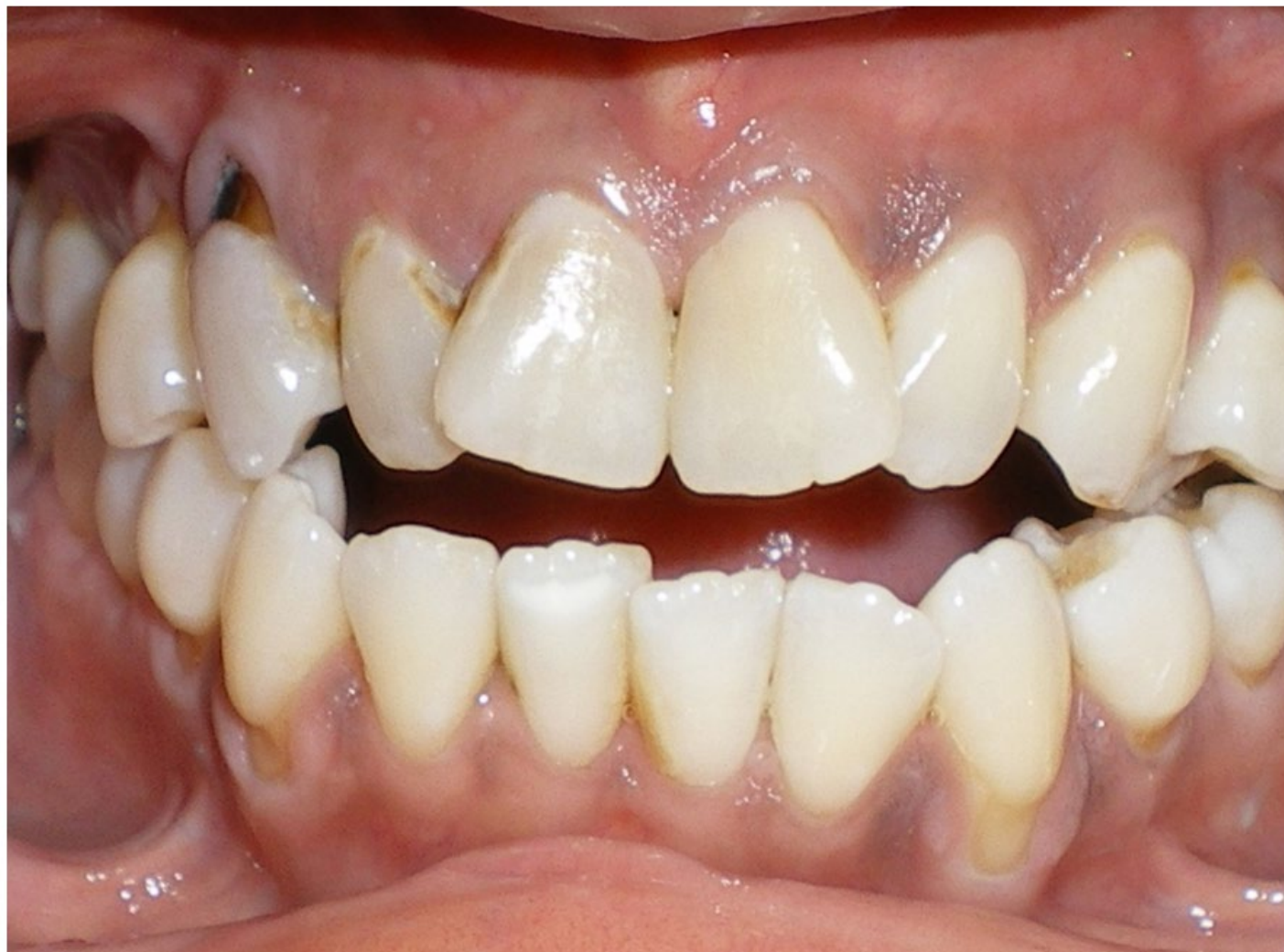Right

Left

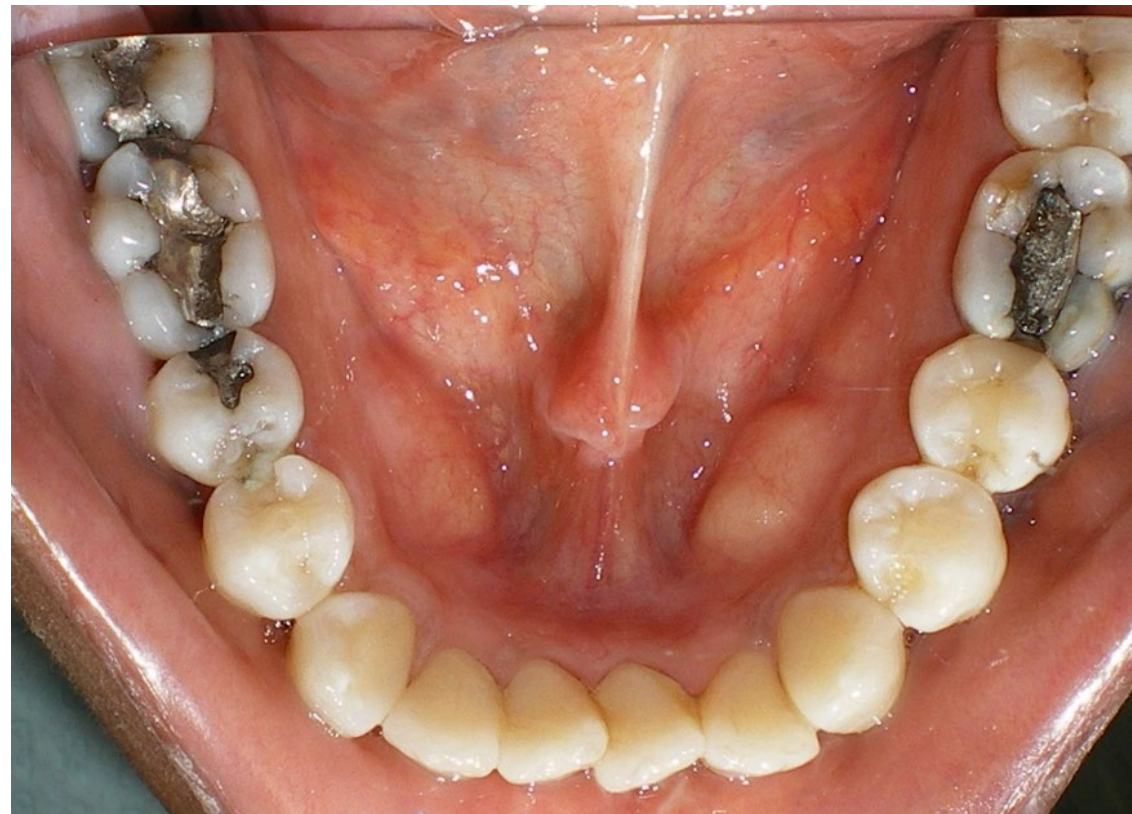
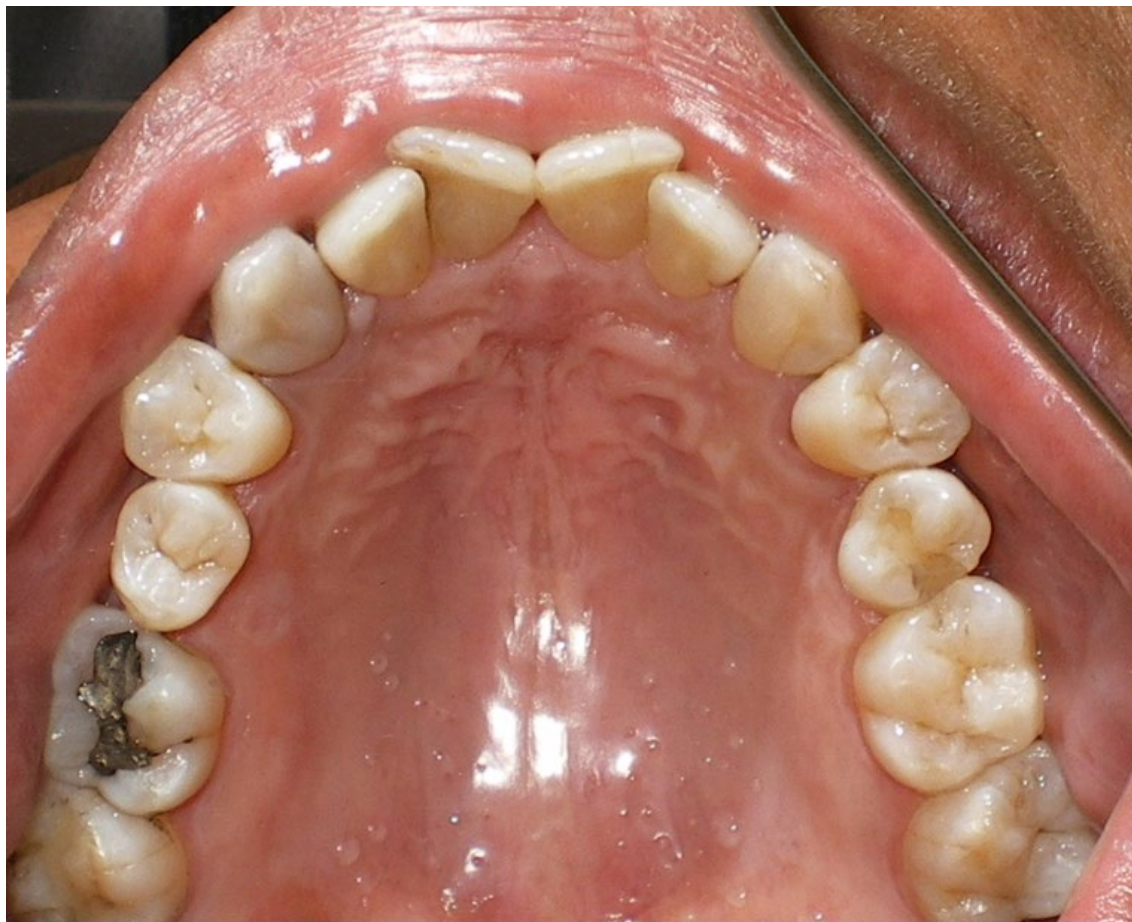FMX



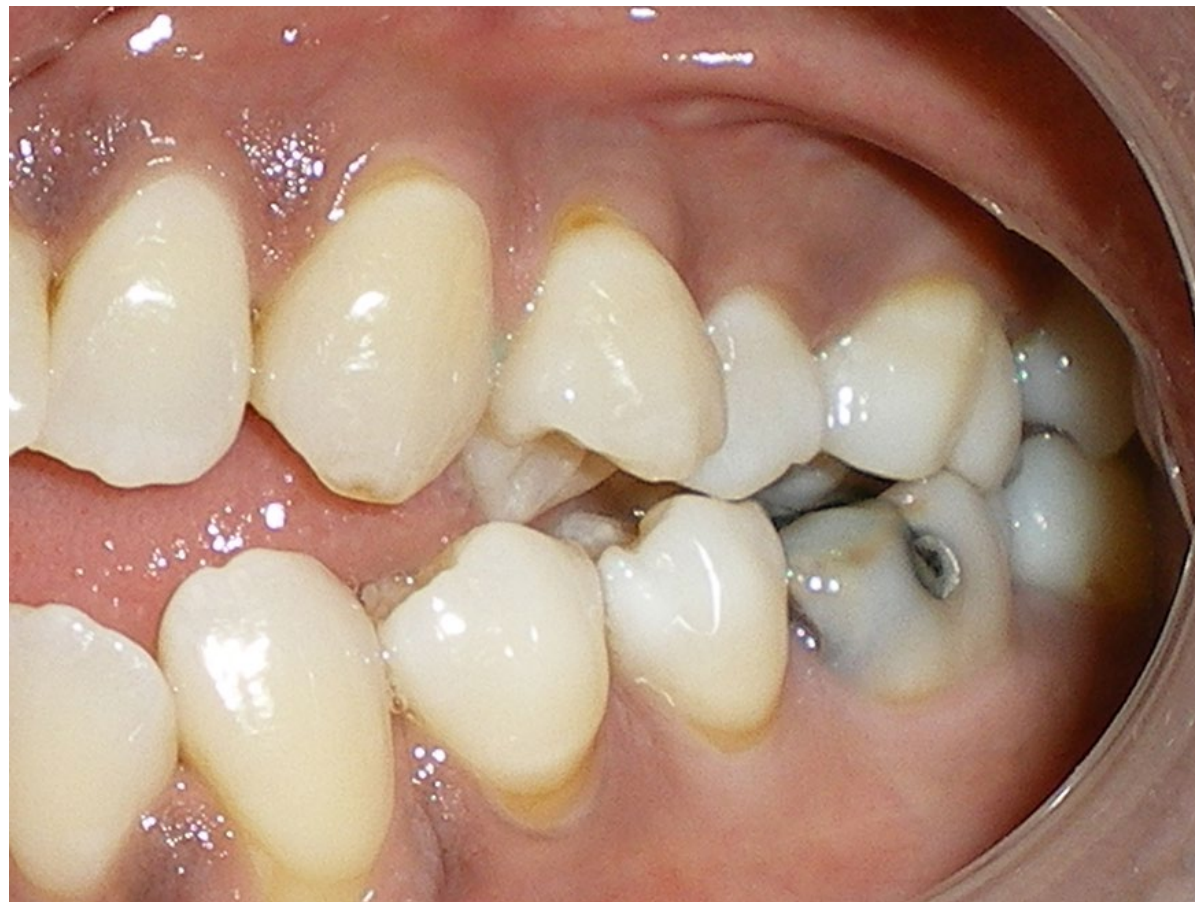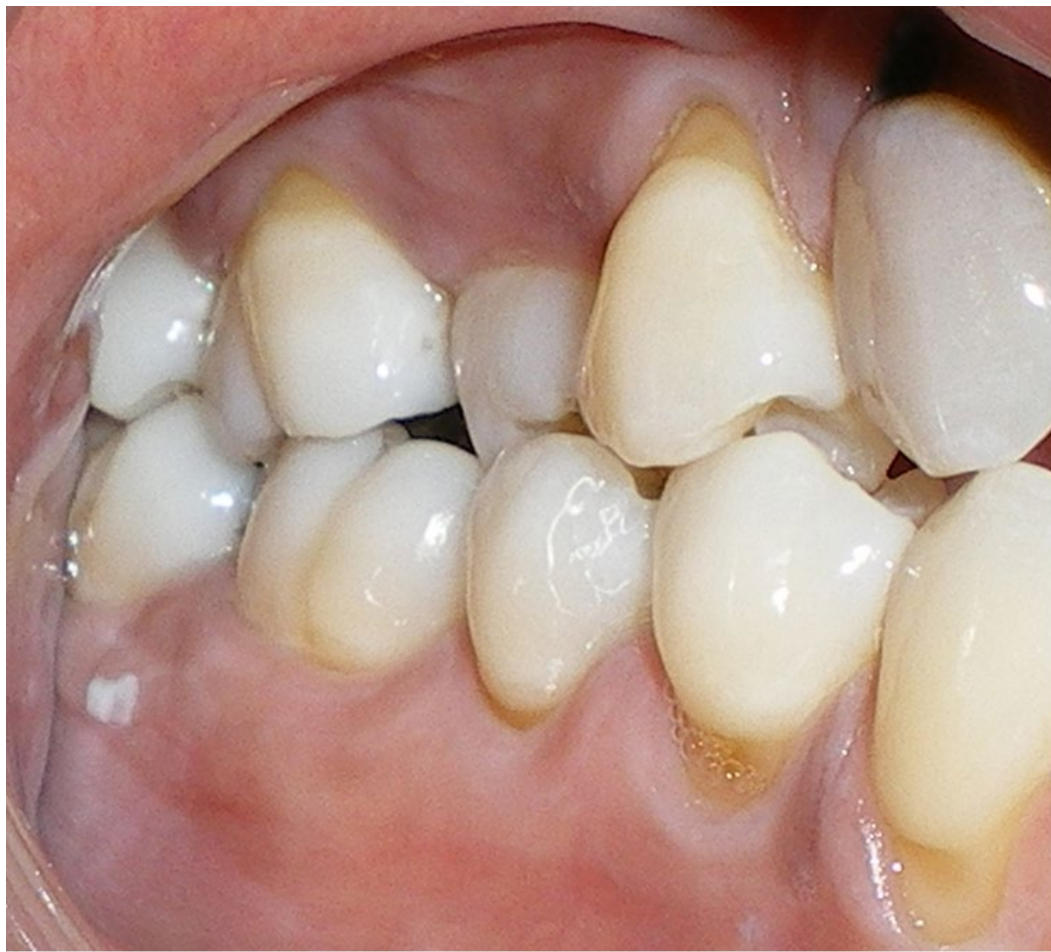Photograph



Photographs



Photographs



Case Sample Question 1

What instrument is best for calculus removal on the distal root surface of tooth 14?

- A. Beavertail ultrasonic tip
- B. Gracey 13/14 curet (Key)
- C. Mini Gracey 15/16 curet
- D. Sickle scaler 204S

Case Sample Question 2

Which is the most likely reason the patient has a higher risk of nutritional deficiency?

- A. Alcohol use disorder (Key)
- B. Cigar smoking
- C. Hypercholesterolemia
- D. Hypertension

Case Sample Question 3

Recession of the facial surface of tooth 22 is most likely due to

- A. abfraction.
- B. abrasion. (Key)
- C. attrition.

Case Sample Question 4

Which is the next step in this patient's tobacco cessation program?

- A. Ask
- B. Advise (Key)
- C. Assess
- D. Assist

Case Sample Question 5

The discoloration of the interproximal gingival tissue between the maxillary central and lateral incisors is most likely due to

- A. a tobacco stain.
- B. an amalgam tattoo.
- C. melanoma.
- D. physiologic pigmentation. (Key)

Case Sample Question 6

Which describes the orientation of the maxillary right second premolar?

- A. Buccoversion
- B. Intraversion
- C. Labioversion
- D. Torsoversion (Key)

Case Sample Question 7

What is the clinical attachment level of the mandibular right canine?

- A. 2 mm
- B. 4 mm
- C. 5 mm (Key)
- D. 6 mm

What tooth most likely demonstrates Class V caries?

- A. 6 (Key)
- B. 14
- C. 22
- D. 29

Case Sample Question 9

What tooth demonstrates radiographic evidence of interproximal caries?

- A. 2
- B. 3
- C. 14
- D. 19 (Key)

Which is the most likely etiology of this patient's anterior occlusion?

- A. Crossbite
- B. Parafunctional movement
- C. Pathological migration
- D. Tongue thrusting (Key)

Which medication is contraindicated?

- A. Amoxicillin
- B. Doxycycline
- C. Metronidazole (Key)
- D. Nystatin

Which medication could be safely administered?

- A. Acetaminophen
- B. Aspirin
- C. Hydrocodone
- D. Nitrous oxide (Key)

Which should be included in the treatment plan?

- A. Air polishing
- B. Antibiotic premedication
- C. HbA1c test
- D. Nutritional counseling (Key)

Case Sample Question 14

Which ethical principle would be violated if the patient's alcohol abuse is discussed among staff members?

- A. Confidentiality (Key)
- B. Informed consent
- C. Paternalism
- D. Veracity

Which condition might this patient be predisposed to?

- A. Asthma
- B. Diabetes
- C. Gastroesophageal reflux (Key)
- D. Muscle spasms