

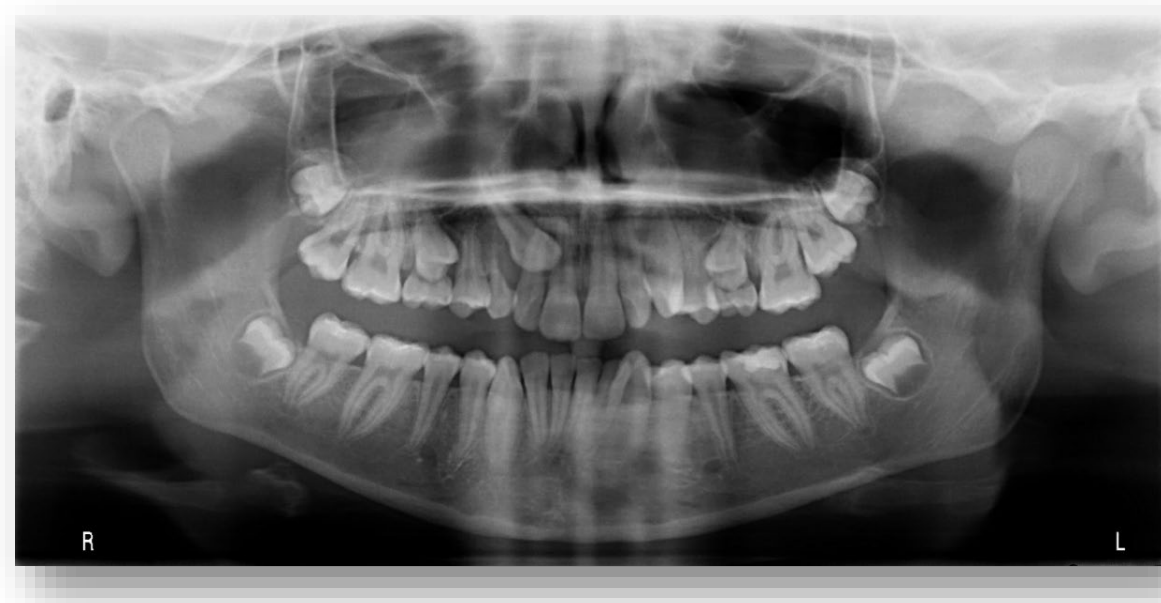Integrated National Board Dental Examination (INBDE)

Sample Questions

American Dental Association (ADA)
Department of Testing Services (DTS)

Sample Question 1

This panoramic radiograph was taken from a 10-year-old female patient. Which permanent tooth is LEAST likely to spontaneously erupt?

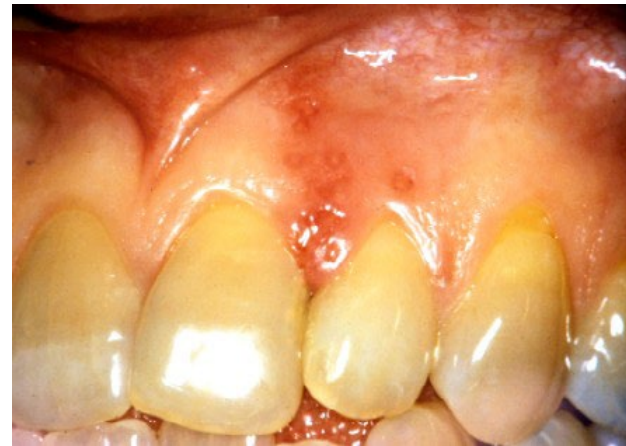

- A. 1
- B. 4
- C. 6
- D. 13

Key: C
FK: 1, 4, 6
CC: 5, 1, 7

Patient
Male, 32 years old
Chief Complaint
"My gums hurt over my front tooth."
Background and/or Patient History
Recurrent gingival lesion Outbreaks last 7 to 10 days.
Current Findings
Vesicular lesion between teeth 9 and 10

Which is the best treatment for the lesions on the labial buccal mucosa?



- A. Dexamethasone elixir
- B. Nystatin suspension
- C. Tetracycline oral rinse
- D. Valacyclovir (Valtrex[®]) tablets

·Key: D
FK: 7, 6, 8
CC: 26, 18, 5, 3, 23

Patient
Male, 48 years old
Chief Complaint
"I've been in pain for two days and now my face is swollen."
Background and/or Patient History
Hypertension Type 2 diabetes
Allergies: Penicillin
Current Findings
BP: 150/93 Temp: 100.3°F Blood glucose: 240 mg/dL Facial edema Lymphadenopathy Extensive apical radiolucency associated with tooth 6

Patient Box is associated with Sample Questions 3 and 4.

Where is the infection most likely located?

- A. Buccal vestibule
- B. Canine space
- C. Nasal cavity
- D. Pterygomaxillary space

Key: B
FK: 6, 2
CC: 1, 2, 18

Patient
Male, 48 years old
Chief Complaint
"I've been in pain for two days and now my face is swollen."
Background and/or Patient History
Hypertension Type 2 diabetes
Allergies: Penicillin
Current Findings
BP: 150/93 Temp: 100.3°F Blood glucose: 240 mg/dL Facial edema Lymphadenopathy Extensive apical radiolucency associated with tooth 6

Patient Box is associated with Sample Questions 3 and 4.

Which antimicrobial agent is most appropriate to prescribe?

- A. Amoxicillin and clavulanate (Augmentin®)
- B. Cephalexin
- C. Clindamycin (Cleocin®)
- D. Metronidazole (Flagyl®)

Key: C
FK: 8, 6, 7
CC: 26, 18

Patient
Male, 5 years old, accompanied by parent
Chief Complaint
Parent: "We're here for my son's follow-up exam."
Background and/or Patient History
First dental examination was two weeks ago. Restorable caries on one or more primary molars in every quadrant.
Current Findings
Patient is nervous, but cooperative

After explaining the procedure, which management technique should be used during the first restorative appointment?

- A. Demonstrate
- B. Rationalize
- C. Restraint
- D. Sedate

Key: A
FK: 9
CC: 1, 15, 14. 45

Patient
Female, 12 years old
Chief Complaint
"My mouth hurts."
Background and/or Patient History
Four first premolars extracted 24 hours ago
Current Findings

Post-treatment discomfort is best managed with

- A. acetaminophen and oxycodone (Percocet®).
- B. codeine.
- C. ibuprofen (Motrin®).
- D. tramadol.

Key: C
FK: 8
CC: 26, 19, 32

Patient
Male, 64 years old
Chief Complaint
"My tooth has turned dark gray."
Background and/or Patient History
Prosthetic heart valve placed three years ago No known allergies
Current Findings
Necrotic tooth 24 Tooth 24 is not responsive to cold. No swelling is present.

Which medication should be prescribed prior to extracting tooth 24, if any?

- A. Amoxicillin, 2 grams to be taken 60 minutes before procedure.
- B. Clarithromycin (Biaxin[®]), 500 milligrams to be taken 60 minutes before procedure.
- C. Clindamycin (Cleocin[®]), 600 mg to be taken 60 minutes before procedure.
- D. No antibiotic administration is required.

Key: A
FK: 8, 6
CC: 26, 32

Patient
Male, 35 years old
Chief Complaint
"I've had a metallic taste in my mouth for the past few days."
Background and/or Patient History
<p>Good oral hygiene Several implants Several restorations recently completed:</p> <ul style="list-style-type: none"> • Gold crown, tooth 2 • MOD amalgam, tooth 3 • Zirconia crown, tooth 4 • Porcelain-fused-to-metal (PFM) fixed partial denture, teeth 29 to 31
Current Findings

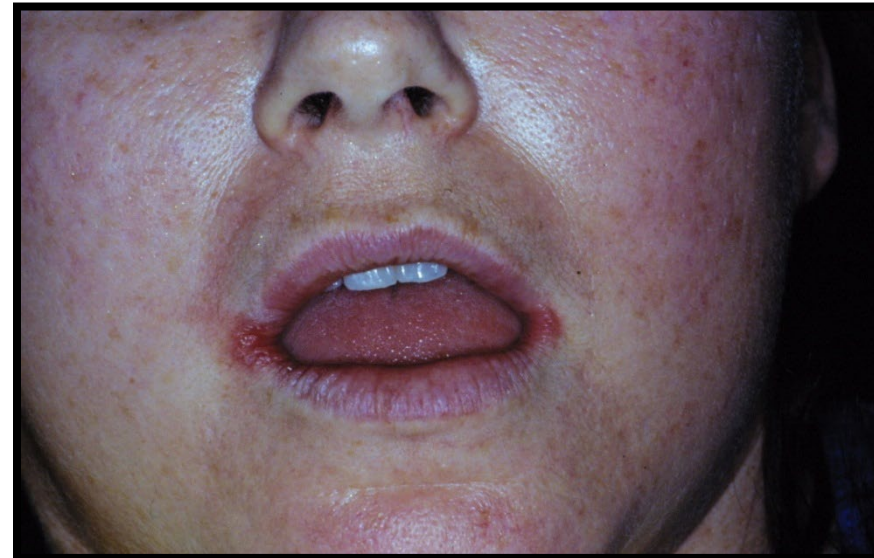Which is the most likely cause of the chief complaint?

- A. Interaction between gold and amalgam
- B. Interaction between zirconia and amalgam
- C. PFM fixed partial denture
- D. Titanium implants

Key: A
FK: 3
CC: 1, 2, 6

Patient
Male, 14 years old
Chief Complaint
"I can't seem to get rid of the sores at the corners of my mouth."
Background and/or Patient History
<p>Allergies: Penicillin</p> <p>Painful, recurrent lesion that never goes away entirely</p>
Current Findings

Which is the most appropriate treatment?

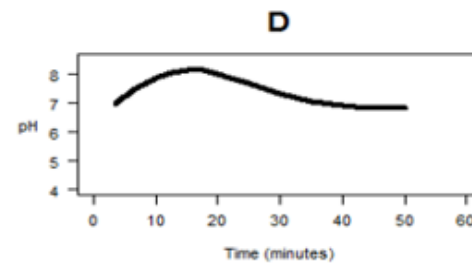
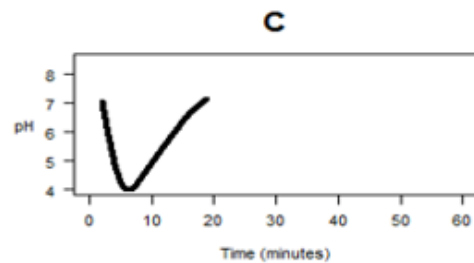
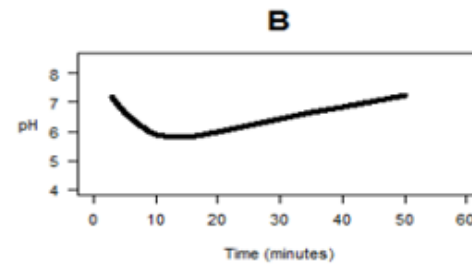
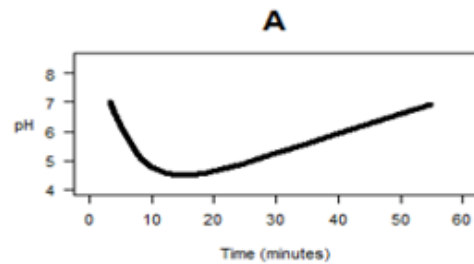


- A. Acyclovir (Zovirax®) cream
- B. Amoxicillin (Amoxil®) capsules
- C. Clindamycin (Cleocin®) capsules
- D. Nystatin and triamcinolone cream

Key: D
FK: 8, 7
CC: 26, 5

Sample Question 10

A person drinks a 12-ounce can of a carbonated sugary beverage but does not ingest any food. Which graph best shows the most likely plaque pH response?



Key: A
FK: 10, 2
CC: 21, 5

Patient
Male, 60 years old
Chief Complaint
"My gums bleed easily."
Background and/or Patient History
Paroxysmal supraventricular tachycardia Pulmonary embolism Type 2 diabetes Hypertension Hyperlipidemia Medications: aspirin, 81 mg daily atorvastatin (Lipitor®) metformin (Glumetza®) warfarin
Current Findings
BP: 145/90 Diffuse gingival bleeding

Patient Box associated with Sample Questions 11 and 12.

Which medication is contributing to the patient's chief complaint?

- A. Aspirin
- B. Atorvastatin (Lipitor®)
- C. Metformin (Glumetza®)
- D. Warfarin

Key: D
FK: 6, 7, 8
CC: 1, 2, 6, 27

Patient
Male, 60 years old
Chief Complaint
“My gums bleed easily.”
Background and/or Patient History
Paroxysmal supraventricular tachycardia Pulmonary embolism Type 2 diabetes Hypertension Hyperlipidemia Medications: aspirin, 81 mg daily atorvastatin (Lipitor®) metformin (Glumetza®) warfarin
Current Findings
BP: 145/90 Diffuse gingival bleeding

Patient Box associated with Sample Questions 11 and 12.

Which laboratory result would provide the etiology for the patient’s chief complaint?

- A. Hemoglobin A1c (HbA1c)
- B. International normalized ratio (INR)
- C. Partial thromboplastin time (PTT)
- D. Platelet count

Key: B
FK: 2, 8, 6
CC: 3, 6, 1, 7

Patient
Male, 9 years old, accompanied by parent
Chief Complaint
Parent: "My son was hit in the face with a baseball and he's bleeding and missing a tooth!"
Background and/or Patient History
Type 1 diabetes
Current Findings
Avulsed tooth 8 Fractured tooth 7

Patient Box associated with Sample Questions 13, 14, and 15.

Which question is most important to ask the parent first?

- A. "Did the child lose consciousness?"
- B. "Do you have the teeth?"
- C. "When did the child last eat?"
- D. "When did the injury occur?"

Key: A
FK: 9, 6
CC: 1, 18, 11

Patient
Male, 9 years old, accompanied by parent
Chief Complaint
Parent: "My son was hit in the face with a baseball and he's bleeding and missing a tooth!"
Background and/or Patient History
Type 1 diabetes
Current Findings
Avulsed tooth 8 Fractured tooth 7

Patient Box associated with Sample Questions 13, 14, and 15.

Which is the best way to advise the parent to protect the avulsed tooth if reimplantation is desired?

- A. Keep the tooth hydrated in a cup of milk.
- B. Place the tooth back into the socket with adult supervision.
- C. Place the tooth in a napkin that is wet with cold water.
- D. Place the tooth under the tongue with adult supervision.

Key: B
FK: 6, 1
CC: 17, 18

Patient
Male, 9 years old, accompanied by parent
Chief Complaint
Parent: "My son was hit in the face with a baseball and he's bleeding and missing a tooth!"
Background and/or Patient History
Type 1 diabetes
Current Findings
Avulsed tooth 8 Fractured tooth 7

Patient Box associated with Sample Questions 13, 14, and 15.

The crown of tooth 7 has not been found. Which is the most appropriate the first step?

- A. Ask parent if there was a pre-existing fracture.
- B. Evaluate pulpal status.
- C. Perform a pulpotomy.
- D. Take radiograph of lower lip.

Key: A
FK: 6, 1
CC: 3, 5, 11, 17

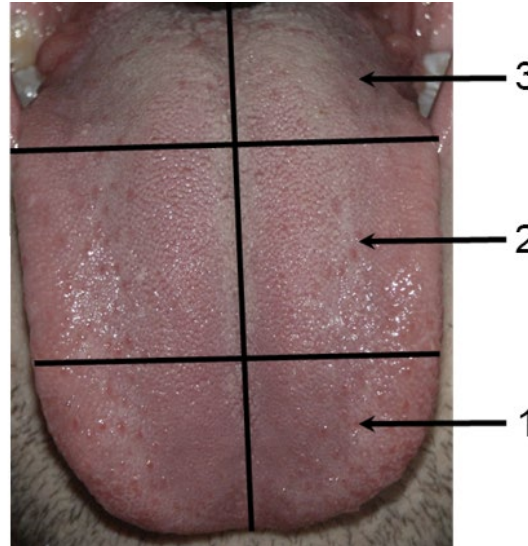
Which image would be most helpful in diagnosing a mandibular fracture?

- A. Bitewing radiograph
- B. Lateral cephalometric radiograph
- C. Panoramic radiograph
- D. Periapical radiograph

Key: C
FK: 3
CC: 10, 7

Patient
Male, 38 years old
Chief Complaint
"I haven't been able to taste on the left side of my tongue for the past three days."
Background and/or Patient History
Left inferior alveolar nerve block was performed during dental treatment three days ago.
Current Findings

Where would loss of taste be expected?



- A. Area 1 only
- B. Area 2 only
- C. Areas 1 and 2 only
- D. Areas 1, 2, and 3

Key: B
 FK: 6, 1, 2
 CC: 2, 6, 27, 1

Patient
Male, 75 years old
Chief Complaint
"I'm here to have my filling done."
Background and/or Patient History
Atrial fibrillation Medications: dabigatran (Pradaxa®) metoprolol (Toprol® XL)
Current Findings

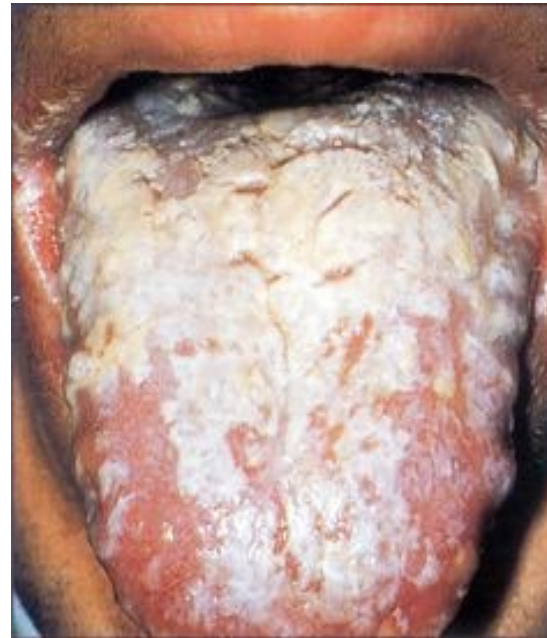
The procedure results in a carious exposure of the pulp. The patient chooses to have the tooth extracted. Which precaution, if any, must be taken prior to performing the extraction?

- A. Instruct patient to discontinue dabigatran (Pradaxa®) the morning of the appointment.
- B. Obtain an international normalized ratio (INR) level the morning of the procedure.
- C. Proceed without treatment modification.
- D. Use lidocaine 2% with epinephrine 1:50,000.

Key: C
FK: 6, 8
CC: 27, 32, 20

Patient
Male, 37 years old
Chief Complaint
"I have white stuff on my tongue."
Background and/or Patient History
Recurrent low-grade fever and fatigue Patient periodically feels cold and a little ill.
Current Findings
White coating can be wiped off.

Which is the etiology of this condition?



- A. Bacterial infection
- B. Fungal infection
- C. Viral infection
- D. Vitamin B₁₂ deficiency

Key: B
FK: 6, 7
CC: 6, 18

A drug has a half-life of 4 hours. Upon discontinuing the drug

- A. 87% will be eliminated in 8 hours.
- B. 90% will be eliminated in 24 hours.
- C. 94% will be eliminated in 12 hours.
- D. 94% will be eliminated in 16 hours.

Key: D
FK: 8
CC: 26

Patient
Male, 65 years old
Chief Complaint
"I lost the filling in my back tooth a year ago."
Background and/or Patient History
<p>Medications: aspirin, 81 mg rosuvastatin (Crestor®)</p> <p>Smoker (cigarettes), 40 pack-year history Dental phobia</p>
Current Findings
BP: 190/100 Height: 6' 1" Weight: 325 lbs

A referral to the patient's primary healthcare provider is most urgent for the treatment of

- A. anxiety.
- B. hypertension.
- C. obesity.
- D. smoking.

Key: B
FK: 6
CC: 8, 16, 52, 11

When making decisions about patient treatment, which type of study provides the strongest evidence?

- A. Case-control
- B. Cohort
- C. Double-blind randomized
- D. Systematic review

Key: D
FK: 10
CC: 41

Patient
Male, 57 years old
Chief Complaint
"I need a checkup"
Background and/or Patient History
Current Findings
Noncavitated demineralized lesion on occlusal surface, tooth 13

Which is the most appropriate management for the lesion?

- A. Apply silver diamine fluoride every six months.
- B. Place a resin restoration.
- C. Place an amalgam restoration.
- D. Provide oral hygiene instruction and reevaluate.

Key: D
FK: 6
CC: 5, 3

Which statement is correct regarding melanoma?

- A. It is formed by malignant Langerhans cells.
- B. It is often associated with chronic actinic damage.
- C. It often has well-demarcated borders.
- D. The depth of invasion is not important in establishing a prognosis.

Key: B
FK: 6, 4
CC: 8

A patient has a maximum opening of 25 mm. Each of the following could be a contributing factor EXCEPT one. Which is the EXCEPTION?

- A. Condylar ankylosis
- B. Fatigue of the masseter muscle
- C. Hypertrophy of the coronoid process
- D. Pericoronitis

Key: B
FK: 6, 1
CC: 5, 2

Patient
Male, 45 years old
Chief Complaint
“My teeth look bad and are loose. I also have a sore throat and I don’t feel good.”
Background and/or Patient History
Malaise for the past four to five days Smoker (cigarettes), 12 pack-year history Patient works in a factory.
Current Findings
Temp: 101°F Bilateral tender anterior cervical lymph nodes Bilateral enlargement of tonsils

Which is the most likely cause of the oropharyngeal signs and symptoms?

- A. Hand, foot, and mouth viral infection
- B. Mononucleosis
- C. Streptococcal pharyngitis
- D. Varicella zoster infection

Key: C
FK: 6, 7
CC: 8, 5, 3, 1, 2

Patient
Male, 48 years old
Chief Complaint
“My jaw hurts when I chew and I cannot open my mouth very wide.”
Background and/or Patient History
Health history is noncontributory. Medications: none Patient presents for regularly scheduled prophylaxis appointments. Patient recently assumed an executive position in a large company.
Current Findings
Maximum opening: 20 mm Sensitivity to palpation of masseter, temporalis, and pterygoid muscles

Each of the following is appropriate to include in the initial management of this patient EXCEPT one. Which is the EXCEPTION?

- A. Bite plane splint therapy
- B. Diet modification
- C. Minor occlusal adjustment
- D. Prescription for a muscle relaxant

Key: C
FK: 6, 2, 1
CC: 1, 2, 3, 34, 35

Which is the greatest threat to pulp vitality during crown preparation?

- A. Bacteria
- B. Desiccation
- C. Heat
- D. Pressure

Key: C
FK: 2, 3
CC: 20, 30

Which base or liner may interfere with the polymerization of a composite resin restoration?

- A. Calcium hydroxide
- B. Compomer
- C. Glass ionomer
- D. Zinc oxide eugenol

Key: D
FK: 3
CC: 30, 21

Each of the following statements is correct regarding taurodontism EXCEPT one. Which is the EXCEPTION?

- A. It may affect permanent or primary teeth.
- B. It occurs in patients with amelogenesis imperfecta and Down syndrome.
- C. Teeth have an unusual root shape due to late invagination of the Hertwig epithelial root sheath.
- D. Teeth have larger pulp chambers due to occlusally displaced furcation.

Key: D
FK: 4, 2
CC: 1, 5

Patient
Male, 16 years old, accompanied by parent
Chief Complaint
"I am here for my cleaning."
Background and/or Patient History
<p>Medications: albuterol (Ventolin® HFA)</p>
Current Findings
White plaque covering the areas of the posterior hard and soft palatal mucosa

Which is the most likely diagnosis?

- A. Candidiasis
- B. Herpangina
- C. Stomatitis
- D. Streptococcal pharyngitis

<p>Key: A FK: 2, 7 CC: 5, 6, 4, 1, 3</p>

Patient
Female, 59 years old
Chief Complaint
"I have many missing teeth and several more are loose. My mouth is also dry."
Background and/or Patient History
Hypertension Medications: aspirin, 81 mg hydrochlorothiazide and triamterene (Dyazide®)
Current Findings
Several missing teeth Many remaining teeth exhibit Class 1 to 2 mobility. Patient wants to save as many teeth as possible. Intraoral examination reveals profound mucosal dryness. Manipulation of major salivary gland ducts fails to produce saliva.

Management of the most common opportunistic infection that may occur in this patient would include which medication?

- A. Amoxicillin (Amoxil®) capsules
- B. Cephalexin capsules
- C. Clotrimazole troche
- D. Nystatin cream

Key: C
FK: 8
CC: 18, 26

Patient
Female, 25 years old
Chief Complaint
“My upper left back tooth has been sensitive to hot, cold and chewing. I woke up in pain last night.”
Background and/or Patient History
Has not seen a dentist for five years. Patient expresses a strong desire to maintain her teeth.
Current Findings
Apical radiolucency, tooth 15 No swelling

Which is most appropriate to include in the emergency treatment of this patient?

- A. Antibiotics and nonsteroidal anti-inflammatory drugs (NSAIDs)
- B. Occlusal adjustment and NSAIDs
- C. Pulpectomy and antibiotics
- D. Pulpectomy and NSAIDs

Key: D
FK: 6, 8
CC: 1, 2, 28, 26

A patient's physician prescribes cephalexin, 2 gm, to be taken prior to dental appointments. On the day of their appointment, the patient presents with a rash, burning in the mouth, and itching on the chest, neck, and arms. Each of the following is an appropriate next step in management EXCEPT one. Which is the EXCEPTION?

- A. Administer diphenhydramine (Benadryl®) and monitor the patient.
- B. Contact the patient's primary healthcare provider to discuss options for treating the patient.
- C. Decrease the dose of cephalexin to 1 gm prior to dental treatment.
- D. Recommend azithromycin (Zithromax®) if an antibiotic is required for future dental treatment

Key: C
FK: 8, 5
CC: 1, 27, 2, 26, 53

Patient
Female, 45 years old
Chief Complaint
"I want to get my teeth checked."
Background and/or Patient History
Patient is new to this dental practice. History of infrequent dental care Self-proclaimed dental phobia The patient reports having traumatic experiences during dental treatment when she was a child.
Current Findings
Multiple caries

Which is the most appropriate first step for the dentist to take after determining the initial oral diagnosis and discussing the treatment plan?

- A. Discuss previous traumatic dental experiences with the patient.
- B. Refer the patient for behavioral therapy.
- C. Schedule all restorative procedures in one appointment.
- D. Schedule all restorative procedures under conscious sedation.

Key: A
FK: 9
CC: 14, 15, 1, 44, 42

Patient
Male, 1 year old, accompanied by parent
Chief Complaint
Parent: "My son fell and a baby tooth came out."
Background and/or Patient History
Patient has never been to a dentist. Family members are patients of record.
Current Findings
Parent presents with patient's avulsed tooth E in a cup of milk.

Which action should be performed by the dentist?

- A. Curette the socket and suture the site.
- B. Inspect the socket and reassure the mother and infant.
- C. Reimplant the tooth and splint to adjacent teeth.
- D. Reimplant the tooth but do not splint.

Key: B
FK: 6, 9
CC: 11, 18, 1, 2

Four posterior teeth are present in the mandibular left quadrant in a 30-year-old patient. One tooth has five cusps, two teeth have four cusps, and another tooth has three cusps. Which tooth appears to be missing?

- A. 18
- B. 19
- C. 20
- D. 21

Key: D
FK: 1, 6
CC: 5, 1, 2

The Occupational Safety and Health Administration (OSHA) bloodborne pathogen standard requires healthcare employers to do each of the following EXCEPT one. Which is the EXCEPTION?

- A. Establish an exposure control plan.
- B. Implement the use of standard precautions.
- C. Make hepatitis C vaccinations available.
- D. Provide personal protective equipment.

Key: C
FK: 9
CC: 47, 51, 49